UNIVERSITY OF ILORIN

THE THREE HUNDRED AND EIGHTH (308TH)
INAUGURAL LECTURE

"BEAUTY OF A SURGEON'S KNIFE: BRINGING SMILES TO PATIENTS' FACES"

By

PROFESSOR (DR.) ABDUS-SAMIU ADEWALE MUSA-OLOMU
(MBBS, M.Sc., Ph.D., *FWACS, FICS***)**

DEPARTMENT OF SURGERY,
FACULTY OF CLINICAL SCIENCES,
COLLEGE OF HEALTH SCIENCES,
UNIVERSITY OF ILORIN, NIGERIA

THURSDAY, 5TH NOVEMBER, 2026

This 308th Inaugural Lecture was delivered under the Chairmanship of:

The Vice-Chancellor

Professor Wahab Olasupo Egbewole, *SAN*
LL.B (Hons.) (Ife); B.L (Lagos); LL.M (Ife); Ph.D. (Ilorin)
FCArb, Fspsp

5th November, 2026

ISBN: 978-978-62700-6-7

Published by:

The Library and Publications Committee,
University of Ilorin, Ilorin, Nigeria

Printed by:
UNILORIN Press, Ilorin, Nigeria



PROFESSOR (DR.) ABDUS-SAMIU ADEWALE MUSA-OLOMU

(MB;BS, M.Sc., Ph.D., FWACS, FICS)

DEPARTMENT OF SURGERY,
FACULTY OF CLINICAL SCIENCES,
COLLEGE OF HEALTH SCIENCES,
UNIVERSITY OF ILORIN, NIGERIA

Courtesies

The Vice-Chancellor,
The Deputy Vice-Chancellor (Academic),
The Deputy Vice-Chancellor (Management Services),
The Deputy Vice-Chancellor (Research, Technology, and Innovation),
The Registrar,
The University Librarian,
Provost, College of Health Sciences,
Dean of Faculty of Clinical Sciences,
Deans of Other Faculties,
Directors of various Centres and Units,
Professors and Other Senate members,
Chief Medical Director, University of Ilorin Teaching Hospital,
Other Principal Officers of the University of Ilorin Teaching Hospital,
Staff Members of University of Ilorin and all Heads of Departments, especially, the Head of Surgery, UITH Community,
My Lords, Spiritual and Temporal,
My Family members, Relations, and Friends,
Scholars and Alumni of the University of Ilorin,
Gentlemen of the Press,
Distinguished Ladies and Gentlemen.

Preamble

بسم الله الرحمان الرحيم

In the Name of Allah, The Most Beneficent, The Most Merciful. I welcome you all to this inaugural lecture. May the peace and blessings of Allah be upon the Prophet of Islam, Prophet Muhammad (PBOH), his Companions of Eminence, each and every one of us from now, till the day of reckoning. I sincerely thank God Almighty for the opportunity and the privilege to deliver this 308th Inaugural Lecture of this *Better by Far* University, University of Ilorin, on this 5th day of November, 2026.

Mr. Vice-Chancellor, the terrible abject poverty in my family was the driving force that made me to have passion for medical practice. I saw it as a profession that would bring a lot of money quickly to bring us out of poverty. However, an elderly father (Baba Jemeel Olomu) in my extended family, saw it as a wrong choice. He mustered us one day and asked us what our future plans were. I mentioned medicine, he shouted in disbelief; ''Medicine? What do you want to do with that? Medicine is for the children of the rich and not for poor or poverty ridden family like ours". He continued, ''…. go and look at Wasiu, he is a bank manager, Musibau is an accountant, so also is Nimota". All his children were accountants and making a lot of money in Lagos then. This left me deeply confused. How do I move from a science course to commercial?

Despite the doubts, I decided to remain on the science path, hoping to identify a lucrative profession that could rapidly improve my family's circumstances. I then decided to be a pilot. I was told they are heavily paid in millions and the whole training is just 81 weeks. Once again, obstacles arose. The secondary school I attended-Nawair-ud-Deen Grammar School, Abeokuta was only 11 years old at the time and had no Physics teacher. As a result, I studied Chemistry and Biology formally, while teaching myself Physics at home after graduation. I meticulously worked through available textbooks, including 'O' *Level Physics* by Abbot, Nekon and Parker. I remain deeply grateful to Messrs 'Dotun and 'Femi Oyewole who established Abeokuta Continuing Education Centre (ABEOCEC), where they taught physics and chemistry respectively to candidates retaking their WASC examinations.

Eventually I passed excellently at my first attempt, with A2 in Biology, A1 Chemistry and A3 in Physics. I got the form for School of Aviation in Zaira, and sat for the Aptitude test in 1979, and I came first. In fact, the Principal of the School, Mr. Bamidele, specifically looked for me for having 100% in the aptitude test and promised to make me the best pilot in Nigeria. Alas, Baba Jameel's words resurfaced; "Pilot is for the rich,

where are you going to get money for the training", which was about five (5) million Naira then in 1980 (Oro agba bi ko se l'owuro, a se l'ale – The words of Elders must come to pass; if not now, certainly later). There was no money for the school fees and the principal did all he could to get me scholarship to no avail. In addition to that, my father called me and seriously warned me to desist in engaging in a very delicate job. If we recollect, in 1980, President Shehu Shagari sent a delegation of 27 Nigerians to the Republic of Sao Tome. On their way back, they had a plane crash and all perished in the sea. So, my elder sister, Sister Sherifat, reported my aviation ambition to my father, citing the tragedy. This further angered and worried him.

Consequently, I decided to settle for Medicine, my original plan. This was further reinforced by my repeated visits with my late mother to Professor 'Biyi Afonja (former Commissioner for Education in the old Western region then) (my mother was nee Afonja – from Afonja Family of Yewaland in Ogun State), looking for ways of helping me for the post primary education. He eventually facilitated the opportunity for me to win the Western State Government Scholarship for my secondary school education. Another strong influence was Dr. Dapo Afonja, a distinguished physician and the immediate younger brother of Prof. 'Biyi Afonja. After each visit, my mother would say: ''Semiu, se oti ri Johnson ati Dapo - komisona ati dokita? Ko tete mo iyi ti o maa se n'ibe.'' ("Semiu, you have seen Johnson and Dapo - a State Commissioner and a Medical Doctor - respectively, so you should decide early which one you want to become.") In addition to that, there was one Dr. Majekodunmi at the General Hospital Ijaiye, Abeokuta, then. He was an Orthopaedic Surgeon. He was a motivator.

I eventually went for Higher School Certificate (HSC) at Ogun State Polytechnic, now Moshood Abiola Polytechnic (MAPOLY) in 1979 and passed Physics, Chemistry and Biology in flying colours. I gained admission into University of Ibadan (UI) in 1981 to read Medicine and Surgery and finished in 1986. I decided to do General Surgery in Residency Training at

University College Hospital (UCH), Ibadan, because I had the notion it must encompass all other sub-specialities of Surgery (all in an attempt to be able to dabble into other sub-specialities to make more money to wipe off poverty which was my original intention).

Introduction

The Vice-Chancellor Sir, the establishment of Medical School in the University of Ilorin was in 1977. The Faculty of Clinical Sciences (FCS) started out as Faculty of Health Sciences, and from inception, it was obviously built for the achievement of great feats. To corroborate this on the 19th of May 1980, 3 years after, Professor Adeoye Adeniyi delivered the first Inaugural Lecture in the College and the 4th in the University, titled "*Child Care in Nigeria: A Critical Appraisal of Some Modern and Traditional Concepts*." This lecture was significant as it marked the beginning of the Faculty of Health Sciences at the University of Ilorin, now known as the Clinical Sciences. Adeniyi's lecture was a pivotal moment in the history of child care education in Nigeria, providing a critical appraisal of both modern and traditional concepts of child care. Nonetheless, following College Organisation and Administrative Structure in 1981, a structured administration for the College was adopted, later refined in 1983 and then in 2004. However, when the Faculty of Health Sciences evolved into the College of Health Sciences in 2004, the Faculty of Clinical Sciences was birthed the same year.

Since its establishment in 2004, many inaugural lectures had been delivered in the Faculty. The first to deliver in the Faculty was Professor Bababode Bojuwoye, the 72nd Inaugural Lecture in the University delivered on the 13th May, 2004 titled: "*Of Bacterial Pathogens and Diarrhoea: Making the Visible and the Invisible Link*." The lecture described diarrhoea as one of the leading childhood killer diseases. However, in the Department of Surgery, seven (7) Inaugural Lectures had been delivered, so far. The first was Professor S.B. Agaja, who delivered the 92nd Inaugural Lecture in the University on the 15th July, 2010 titled

"*Surgery: The Anchor of Life*". The second was Professor Ismaila Adigun-Lawal, a plastic surgeon, who delivered the 122nd Inaugural Lecture on the 7th February, 2013, titled "*A Plastic and Reconstructive Surgeon in a Developing Country: Practice, Problems, and Prospects*."

The third in the department was Professor J.O. Adeniran, the first Paediatric Surgeon in the department, who delivered the 179th Inaugural Lecture, titled "*Of Monstrosities in Children*" on 15th March, 2018. The fourth was Professor S.A. Kuranga, the first Urologist in the department, who delivered the 180th Inaugural Lecture titled: "*The Experience of a Urological Surgeon in Sub-Saharan Institution*" on 13th September, 2018. The fifth was Professor P.O. Adeoye, the first Cardiothoracic Surgeon, who delivered the 216th Inaugural Lecture titled: "*Battling to Keep our Hearts: Who will Heal the Bleeding Hearts*?" on 10th February, 2022. The sixth was Professor L.O. Abdur-Rahman, the second Paediatric Surgeon in the department, who delivered 222nd Inaugural Lecture titled "*Intrigues and Intricacies of Children's Surgery for Restoring Smile and Hope for the Future*" on the 22nd December, 2022. The seventh was Professor Ademola Alabi, the second Urologist in the department, who delivered the 250th Inaugural Lecture in the University titled "*That All May Pee in Peace*" on the 21st December, 2023.

Mr. Vice-Chancellor, the title of my lecture is "**Beauty of a Surgeon's Knife: Bringing Smiles to Patients' Faces**". I am the First General Surgeon to deliver an inaugural lecture in the Department of Surgery, University of Ilorin. It is often sad to get sick/ill, because of the fear of the outcome, which can be either wellness or death. When it happens, the person prays to get well as soon as possible. The sadness becomes more compounded, if you are told, you need a surgical operation to get well. However, if all goes well in the hands of skilful experts and taking the necessary precautions, the patient often smiles at the end. Hence, the title is chosen to elucidate some of my skills as a general surgeon and how I had put smiles on the faces of my

patients. As a General Surgeon, it is pertinent to begin by defining General Surgery and outlining the vital roles the General Surgeons play in the critical healthcare of humanity. General Surgery is a surgical specialty that focuses on abdominal contents including oesophagus, stomach, small bowel, colon, liver, pancreas, gallbladder and bile ducts, and often the Thyroid gland. They also deal with diseases involving the skin, soft tissue, hernias and breast**.** Nevertheless, General Surgeons must be able to deal initially with almost any surgical emergencies. Often, they are the first point of call to critically ill or gravely injured patients, and must perform a variety of procedures to stabilise such patients, such as thoracostomy, cricothyroidotomy, compartment fasciotomies and emergency laparotomy or thoracotomy to stanch bleeding. General surgeons are also commonly in charge of staff surgical intensive care units or trauma intensive care units (Schwartz, 2019). Furthermore, the certified General Surgeon is expected to be able to recognise and provide early management and appropriate referral for urgent and emergent problems in the surgical fields of: Gynaecology, Urology, Orthopaedic Injuries, Hand Surgery, Neuro-Surgery – bore holes for brain injuries, among others (**Musa** *et al.,* 2008).

Mr. Vice-Chancellor, my Sub-speciality as a General Surgeon is Thyroid Surgery and application of Principles of Surgery to manage emergencies and other dreadful surgical conditions in other sub-specialities of surgery other than General Surgery. It also outlines General Surgery Techniques to treat surgical patients, especially in the areas of Paediatric Surgery, Cardiothoracic, Urology, Obstetrics and Gynaecology, Anaesthesia among others. The thyroid gland is an endocrine gland that is located in the anterior part of the neck below the voice box. (Fig.1) The thyroid gland secretes two hormones - Thyiodothyronine (T3) and Thyroxine (T4), which are essential for regulation of metabolic functions of the body.

An enlarged thyroid gland is clinically referred to as Goitre**.** This enlargement may involve the entire gland or present as one or more nodules as shown in (Figs. 2&3). This

enlargement can be due to depletion of the substrates needed in the production of the thyroid hormone, especially iodine. This can be due to non-availability, when depleted in the soil by erosion or the food substance that we consume, suppression of production by drugs that patients use (e.g. cough syrups, anti-hypertensive drugs, antidiabetic drugs; food rich in garbage), as they mop up the iodine reserve in the body. Environmental factors play a significant role too. Fumes generated during cassava flour production (*garri*) (Fig. 4), contain cyanide fumes, (Padmaja, 1995, Koch *et al*., 1994) which, when inhaled, binds iodine in the body and leads to deficiency and subsequently goitre (Achinewhu & Owuamanam, 2001; Pearce *et al*., 2003). This will be experimentally demonstrated later in this lecture. Others include genetic predisposition and spontaneous occurrence in area endemic and pan-endemic varieties. The increase metabolic activities in puberty can also lead to goitre formation. It is the same picture during pregnancy due to fetal growth. Hence, some pregnant women do present with goitre.

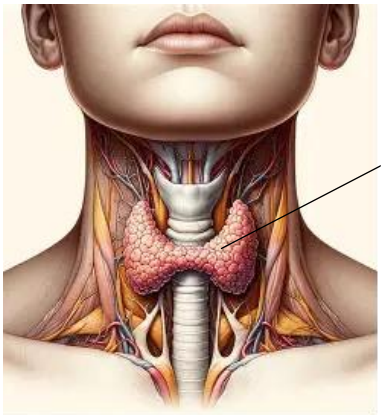

Fig. 1: Thyroid Gland
Source: Ellis (2010)



Fig. 2: Simple (Colloid) Goitre

Source: Bailey and Love (2018)



Fig. 3: Diffuse Multinodular Goitre

Source: Bailey and Love (2018)



Fig. 4: Cassava flour (*garri*) producer

Source: Author's Database (2026)

Types of Goitre

There are four types of goitre, namely: Simple Goitre, Malignant Goitre, Toxic and Inflammatory types**.** Simple goitres occur when the glad enlarges in an attempt to meet metabolic

demands in the presence of iodine deficiency. Simple goitre neither over-function nor under-function, and are the most common types (Fig. 5). Toxic goitres are hyper functioning, which means they are producing more hormones than are needed and these are the ones usually associated with symptoms in individuals like fever, anxiety, palpitations, severe agitation, irregular menstruation, weight loss despite good appetite, diarrhoea, heart failure in the elderly and pointing and protruding eye balls (Fig. 6). Malignant goitres are cancerous, growing spontaneously and sporadically and invading the surrounding structures in the neck, especially the wind pipe and distant parts of body, including lymph nodes, bone; and they can actually lead to the death of an individual, unlike the other types, which are not cancerous (Figs. 7&8). The inflammatory type is not common. It is otherwise known as *thyroiditis* – inflammation due to microorganisms usually bacterial. Bacterial and viral infections are common in the nasal and respiratory system, which often spread to the thyroid gland to cause inflammation of the gland.



Fig. 5: Simple Goitre
Source: Musa, *et al.* (2005)



Fig. 6: Thyrotoxic goitre (goitre), illustration.
Goitre (swollen neck), pointing and protruding eye balls
Source: Author's Database (2026)



Malignant Type

Fig. 7: Patient with thyroid cancer and spread of thyroid cancer to the left lateral chest wall

Sources: Musa *et al.* (2008)



Fig. 8*:* Malignant type with spread to the skull or (head)

Sources: Musa *et al.* (2005)

In my practice, simple and toxic goitres are the most frequently encountered. We rarely encounter the malignant types, as they are not very common. Nature is very kind to humanity otherwise, if malignant or cancerous is common like others, a lot of patients could have died in their early lives. However, goitre is common in females than males with ratio of about ten to one (10:1)- Hormonal Fluctuations, Autoimmune Diseases, Physiological Demand and Genetic Predisposition are some of the factors responsible in females. (Hegedüs *et al.*, 1986; Krassas, 2000). It is the disease of the females and when seen in males, it is often taken as malignant types, until proven otherwise.

Environmental Causes of Goitre -Cyanide

The Vice-Chancellor Sir, as earlier mentioned cyanide has a significant impact on thyroid gland. This is by depletion of iodine in the body by cyanide fumes. Iodine is needed in the production of thyroid hormones, thereby causing enlargement of thyroid gland (goitre) through its depletion, thereby causes enlargement of the thyroid gland. **Musa-Olomu** *et al*. (2013) conducted a study in 2013 on twenty-one female and male Wistar rats, which were randomly grouped into three of seven rats. Each of the first two groups were treated with different concentrations of cyanide solution (6mg/kgBW and 12mg/ kgBW), respectively and the third was with sucrose solution (0.25M) for 30days.

At the end of the experiment, the rats were killed by cervical dislocation method. Subsequently, they were bled from which serum Free Triiodothyronine (FT3), Free Thyroxine (FT4) and Thyroid Stimulating Hormone (TSH) concentrations were analysed (Table 1). The excised thyroid glands were processed for light microscopic investigation Figs. 8,9&10 while the activities of Glucose-6-Phosphate Dehydrogenase (G6PDH), Lactate Dehydrogenase (LDH), Alkaline Phosphatase (ALP), Malondialdehyde (MDA) and Superoxide Dismutase (SOD) were assayed from the thyroid tissue homogenates (Table 2), to demonstrate the effects of cyanide on metabolic activities in the cells of the thyroid gland.

Table 1: Thyroid Hormones Assay Result**s**

Treatment Dose	**FT3 (Pg/ml)**	**FT4 (Pg/ml)**	**TSH (µIU/ml)**
6mg/Kg	7.71±1.3*	22.09±6.1*	0.15±0.0*
12mg/Kg	4.65±0.4*	11.81±0.8*	0.17±0.0*
0.25M Sucrose	1.03±0.3	9.38±0.6	0.21±0.7

Number of subjects (n) = 6

Mean ± S.E.M = Mean values ± Standard error of mean.
Analysis was done using one way ANOVA. Cyanide cytotoxicity: *significance ($p<0.05$) from control group. Cyanide significantly affected the activity of FT3 ($p=0.00$), FT4 ($p=0.00$) and TSH ($p=0.00$).

The thyroid hormones show the effect of cyanide on the thyroid glands as it causes release of colloids from the thyroid cells leading to over production of the thyroid hormones which eventually leads to thyrotoxicosis/ hyperthyroidism - over functioning of the thyroid gland. Cyanide facilitates the release of colloids from the cells. It also leads to overgrowth of the thyroid gland tissue (through increased metabolism) which leads to goitre formation (Figs. 9,10&11). The amounts of hormones produced in the rats fed with cyanide were more than the control given only sucrose solution, (Table1). TSH-the hormones responsible for the production of FT3, FT4 are lower in the experimental groups (1&2) than the control group (3), because there was over production of the thyroid hormones already. This is by negative feedback mechanism (Figs. 9,10&11).

Table 2: Quantitative Histochemical Result

Treatment Dose	**G6PDH (U/L)**	**LDH (U/L)**	**ALP (U/L)**	**SOD (unit/ml)**	**MDA (nmol/dl)**
6mg/Kg	4876.33 ±2.5*	1369.00± 38.4*	1929.17+ 18.1*	69.67± 1.5*	0.0080±0.0003*
12mg/Kg	4938.50± 3.8*	1470.50+ 51.7*	2648.17+ 19.2*	59.50± 1.3*	0.0127±0.0015*
0.25M Sucrose	4305.17± 210.5	182.33±2.7	326.67±1.7	29.83± 1.7	0.0137±0.0013

Number of subjects (n) = 6

Mean ± S.E.M = Mean values ± Standard error of mean
Analysis was done using one way ANOVA. Cyanide cytotoxicity: *significance ($p< 0.05$) from control group. Cyanide toxicity significantly affected the activity of G6PDHP (=0.00), LDH ($p=0.00$), ALP ($p=0.00$), SOD ($p=0.00$) and MDA ($p=0.00$).

The thyroid hormones are mainly for growth and for body metabolic activities. Thus, (Table 2) shows the results of carbohydrate metabolism within the thyroid gland, which revealed more metabolic activities in the rats treated with cyanide solution (G6PDH, LDH, ALP and SOD). These increased metabolic activities often lead to increase in growth of the gland disproportionately with the other body metabolic activities; and hence the enlargement of the thyroid gland called goitre. We came to the conclusion that cyanide is injurious to thyroid gland cell.

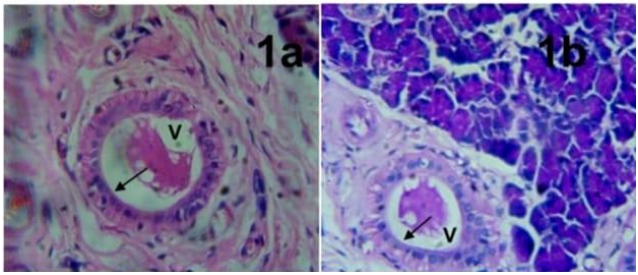

Fig. 9: Normal thyroid gland in the rats treated with sucrose solution with simple tissue growth

Source: Musa *et al*. (2013)

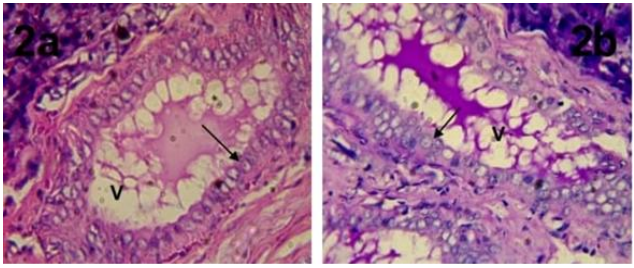

Fig. 10: Injurious effects of cyanide on thyroid gland tissue with increase in growth which appear as tall and extremely excessive tissue growth leading to protrusion of the gland in the neck called goitre

Source: Musa *et al*. (2013)

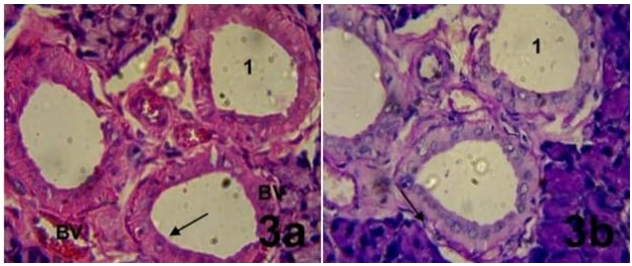

Fig. 11: Experimentally treated groups.

Source: Musa *et al*. (2013)

The above revealed markedly distended follicles and diffusely hyperplastic thyroid follicles lined with tall columnar epithelial cells. Their follicles are vacuolated with scalloped edges. There was an increase in serum FT3, FT4 with decrease serum TSH was obtained in the treated group. Increased levels of G6ADH, LDH, ALP, MDA and SOD were also observed. Activities of the G6PDH, LDH, ALP, MDA, FT3, FT4, and TSH were highly significant when likened to the control group using one-way ANOVA statistical analytical method.

The results showed histological observation of thyroid gland of rats. The injurious effects of cyanide on thyroid gland tissue led to the increase in growth which appear as tall and extremely excessive tissue growth eventually leading to protrusion of the gland in the neck that is called goitre. The thyroid gland tissue is more pronounced here because of higher concentration of cyanide solution (12mg/KgBW). We concluded that cyanide is (cytotoxic) injurious to the thyroid gland and damages the cells. Hence, one should avoid coming close to cassava flour (*garri*) producers while processing garri because of the effects of cyanide fumes on the follicular cells of thyroid gland.

Myth about Aetiology of Goitre and its Surgical Removal

Vice-Chancellor Sir, throughout my research and clinical practice in rural, semi-urban and urban settings, I encountered numerous challenges. Such challenges included ignorance, poverty, cultural beliefs attributing goitre to witchcraft, and

limited access to orthodox medical care. These challenges extended dangerously into treatment practices**.** To address this, I collaborated with *The Nation and Guardian Newspapers* to raise nationwide awareness (Figs. 11-13). Additionally, I developed context-appropriate anaesthetic techniques tailored to available facilities and patient conditions across different settings. I also worked to devise the best methods of anaesthesia that could be applied in the specific areas, urban (**Musa** *et al*., 2009), semi-urban (**Musa** *et al*., 2008) and rural areas (**Musa** *et al*., 2005; 2006) for our patients, depending on the diagnosis, procedure and available facilities (**Musa** *et al*., 2009).



Fig. 12: The NATION Newspaper (2014)

The newspaper publication of the community infested with goitre in Badagry, Lagos and a woman in the community with a very huge goitre.

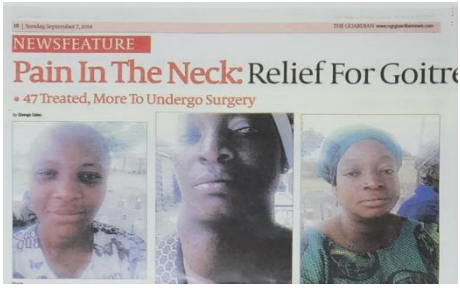

Fig. 13: The Guardian Newspaper (2014)

The Guardian Newspaper publication of the community in Badagry infested with goitre that initially rejected surgical operation and felt sad but the patients felt relieved and happy after the operation.

Mr. Vice-Chancellor, I am pleased to report that these challenges were successfully surmounted, and barriers to the surgical treatment of goitre were permanently removed, (**Musa** *et al*., 2003, 2005, 2006, 2008, 2009). One prevailing belief held that goitre should never be treated surgically, for the fear that surgeons would "slaughter" patients like livestock: ***''oju ni Maalu nro, Obe ko dara lorun'' – The cow endures in silence; the knife is harsh on the throat.*** This we solved by conducting surgical outreaches in the rural communities where these patients dwell. It was the survival of these patients that gave most of our people in the rural areas the courage to surrender themselves to our surgical treatment (**Musa** *et al*., 2008), Again, we devised the methods of operating these patients while awake (using superficial cervical block method of anaesthesia and showing them the goitre after removal that saved the day) (**Musa** *et al*., 2005, 2014). Paradoxically and beautifully, many patients smiled after surgery and expressed deep gratitude. These results perfectly capture the essence of this lecture, implying that the **beauty of a *Surgeons' knife is the smile that it brings to the patients' faces''.***



Fig. 14: Before and after the Surgery

Source: Musa *et al. (*2005)



Figure 15: Before and after the Surgery

Source: INFORMATION NIGERIA news of Tuesday 11th August, 2017

In addition, the fear about surgical treatment of goitre is an erroneous cultural belief rooted in the existence of witchcraft and wizardry. It was built on the belief that goitre was the result of spiritual poisoning (Fig. 16). It is believed that the goitre is the act of witches that poisoned the affected individual, while they slept and that Almighty God, in His mercy, arrested the poison before it could be swallowed (**Musa** *et al.*, 2005). Consequently, it was regarded as an abomination for such a "poison" to be subjected to surgical dissection. The fear was that surgical intervention would release the poison into the body, inevitably leading to death.


THE NATION, SATURDAY, JULY 26, 2014

Goitre-infested community where victims reject medical help

• Blame plight on witches, wizards

Fig. 16: *The NATION* Newspaper (2014)

Newspaper publication of the community infested goitre in Badagry, Lagos State that holds the belief that it is caused by witches, witchcraft and wizardry.

To counter this deeply entrenched belief, **Musa** *et al.* (2005) devised a method of operating on these patients while they remained awake, using the superficial cervical block technique of anaesthesia. By showing the patients and their relatives the excised goitre immediately after surgery, fears were allayed, confidence was restored, and this approach proved decisive in overcoming resistance to surgical treatment.

Thyroidectomy in Rural and Sub-Urban Settings and Development of Musa-Olomu Day-Case Thyroidectomy

Mr. Vice-Chancellor, in my efforts to dispel mythical beliefs and negative cultural attitudes, to address the shortage of anaesthetists, which will be addressed later in the course of this lecture (**Musa** *et al.,* 2005) and to ensure the judicious use of limited healthcare resources, I explored the possibilities of day case thyroidectomy in which a clinically and laboratory screened patient comes to the hospital and earns his/her operations under awake anaesthesia and returns home the same day. Before elaborating on this technique, it is important to restate a fundamental principle of surgery, which holds that ‘‘The applicability of any surgical technique must be in conformity with the principles of surgery, which is safety, efficacy and patients’ comfortability/satisfaction.’’ I am pleased to state that all our patients confirmed this technique to be safe, effective and satisfactory.

Musa-Olomu Day Case Thyroidectomy

The technique of day care thyroidectomy had been practised by a lot of workers (**Musa** *et al.,* 2005), but I had added some modifications that include (i) Local infiltration of 0.05% xylocaine at the incision site with injection of ketamine anaesthesia intravenously and the use of Valium Roche (ii) Use of local infiltration with xylocaine 0.05% with cervical block. The average duration of the operation ranges from one and a half to two and a half hours, while the effect of anaesthesia will last for about 3hrs-4hrs, especially if xylocaine with adrenalin is used. In patients who exhibit anxiety or apprehension, a 5 mg

intravenous dose of Valium (Roche) is administered to achieve adequate sedation and reassurance.



Fig. 17: Anatomical Superficial Cervical Plexus Block

Source: Musa *et al*. (2005)

Surgery is usually commenced at 8:00 a.m., and patients are typically discharged six to eight hours post-operation. Postoperatively, patients are placed on 10mg of oral morphine every four hours, which is well tolerated in combination with 1g of paracetamol. One of the major advantages of this technique is that it allows the surgeon the opportunity to closely observe all the immediate life-threatening complications of thyroidectomy, all of which typically manifest within the first 4hours of surgery – these include vocal cord paralysis, bleeding with difficulty in breathing, injury to external branch of superior laryngeal nerves, and collapse of the trachea. I am glad to inform you and this gathering today that these techniques were presented as a paper in 2004 at the International College of Surgeons Conference in Calabar Nigeria and the paper was rated as the best paper presented that year.

Thyroidectomy in the Rural Setting

In the rural setting, we adopted the option of local infiltration with Lidocaine augmented with injection of intravenous ketamine general anaesthesia (**Musa** *et al*., 2006). This technique was applied at Muslim Hospital Saki between January 1998 and January 2004, and was used successfully in 23 patients. Hence, we have been able to demonstrate that

thyroidectomy can be safely performed in any community setting, urban (**Musa** *et al*., 2008), semi-rural (**Musa** *et al*., 2006), rural setting (**Musa** *et al*., 2005) using general endotracheal anaesthesia, cervical block or local infiltration augmented with Ketamin, injection anaesthesia, depending on available resources and patient suitability.

Amelioration of Thyroidectomy Bleeding

Musa *et al*. (2010) conducted a research on the bleeding patterns of my patients after operation. The neck is well vascularised and the major vessels are in the neck, so patients can bleed after operation. This bleeding when accumulated can cause oedema of the airway and respiratory obstruction leading to death. Hence, we often leave a rubber drain in the operation wound for drainage to prevent respiratory obstruction. Similarly, **Musa** *et al*. (2010) conducted a study to evaluate the necessity, benefits, and limitations of surgical drains as well as their relationship with the cost of care and duration of hospital stay. This was a prospective randomised study involving 67 patients divided into two groups. Group A (35 patients with drains) and Group B (32 patients without drains). All the patients underwent subtotal thyroidectomy, using identical surgical techniques and wound closure methods. No anticoagulants were administered and clotting profiles were within normal limits in both groups. Three patients developed features of respiratory obstructions (respiratory distress and stridor) the first 2, one from each group, was as a result of laryngeal oedema from trauma of difficult intubation.

The third was from group B, as a result of haemorrhage and haematoma collection (she was one of the controlled thyrotoxic patients). Two patients (5.7%) developed wound infection in group A, which increased morbidity, hospital bill and prolonged hospital stay as compared to group B. The highest volume of drainage of 35mls was from a woman with a big goitre (120g). Normal was 25g-50g), while average drainage was 17.7 $\pm$ 6.9mls. We therefore concluded that the routine use of drains is not necessary in the majority of thyroidectomy cases, except in situations involving large residual cavities or copious oozing from highly vascular glands such as controlled toxic

goitres. Identified limitations of drain usage included increased risk of infection and higher hospital costs **Musa** *et al*. (2010).

Gossybipoma: Retained Surgical Instrument, Gauze, Drapes, Cotton Wool

Vice-Chancellor Sir, God Almighty is the only entity that is infallible. Surgeons do make mistakes in the course of their surgical intervention. Inadvertently forgetting surgical instruments, gauze, drapes, cotton wool is one of the major mistakes that often occur. But at the end, our patients will smile home after removal (correction of the mistake). It is essential to state that all these patients were referred to us from other facilities. **Musa** *et al*. (2012) discovered in our practice that some patients, who had surgeries for thyroid gland removal, but their wounds failed to heal, several months after the operation. They were referred to us from other hospitals.

We discovered this was due to the gauze (Gossybipoma, Fig. 18) which was inadvertently left in place to staunch bleeding most often from injury to blood vessels of a retrosternal goitre that had acquired some vascularisation from surrounding vessels. Usually, when the gland is brought into the wound, the vessels were severed and retracted back into the retrosternal area; hence the surgeon could not arrest the bleeding and inadvertently forget the swabs to staunch the bleeding. To address this, we advocated a gentle dissection of retrosternal goitres, careful identification and control of bleeding vessels, meticulous haemostasis, and the strict use of appropriate, sterile surgical materials (Fig. 18).



Fig. 18: Reoperation: Removal of a forgotten gauze from a referred patient post initial thyroidectomy.

Source: Musa *et al*. (2012)



Fig. 19: Patient smiled after removal of forgotten gauze in her neck.
Source: Musa *et al*. (2012)

This captures the topic of this lecture

Hernia

Hernia by definition is a protrusion of a viscus or part of a viscus through an abnormal opening in the walls of its containing cavity (Bailey & Love, 2005). Giant Inguino-scrotal hernia (GIH) is often defined as hernia extending from the pelvis to the mid-thigh down to the knee level. (or the size of a patient head). I worked on Giant Inguinoscrotal Hernia (GIH) for more than 20 years among other hernia types, as I had earlier worked on other types of hernia (**Musa** *et al*., 2007) and also worked on children hernia (**Musa** *et al*., 2004). I feel excited to inform this gathering that in 2014 Annual Conference of West African College of Surgeons' Conference (WACS) in Kumasi, Ghana, my works on GIH were rated as the best (Fig. 20). Repairing GIH as a single staged procedure without organ resection rather than multi-staged where some organs in the abdomen will be removed permanently, was proposed (**Musa** *et al*., 2007).



Figure 20: The Giant Hernia extending below the knees. From the pelvis to the knee with the penis invaginated

Source: Musa et al. (2023)

The patients were often admitted and estimation of their hernia volumes were estimated using a devise designed by me-Musa-Olomu (2007)-Water Can Measurement Device (MOWCMD) applying Archimede's Principle.



Fig. 21: Measuring the volume of the GIH using Archimedes' Principle (**Musa-Olomu** water-can measuring device, MOWCMD)

Source: Musa *et al.* (2023)

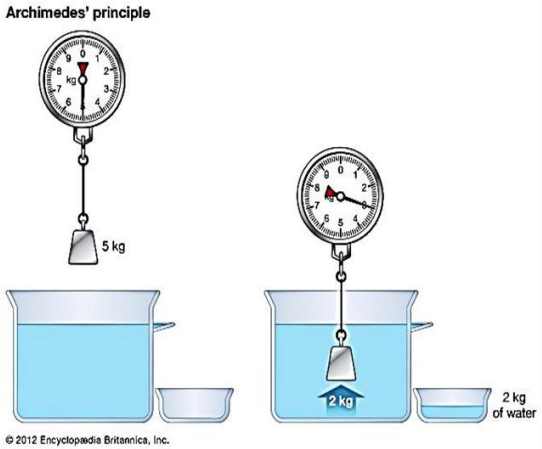

Fig. 22: Archimedes' Principle (2012)

According to the Principle, "the upward buoyant force that is exerted on a body immersed in a fluid, whether fully or partially, is equal to the weight of the fluid that the body

displaces". It is a law of physics fundamental to fluid mechanics. It was formulated by Archimedes' of Syracuse from simple Physics.

W=V x D

Wkg= Vm^3 x D kgm^{-3}------1

Therefore, V =$\frac{wt}{D}$ $\frac{\text{Kg}}{Kg-3}$ ------2

But, Density of water = $1kgm^{-3}$

Therefore, Volume of water displaced = weight of the water displaced.

This measurement is necessary because we have discovered over the years that hernia volumes more than 4 litres were often difficult to repair as a single stage procedure without organ resection. The volume estimated was 3.45litres for this patient presented. Find from the table the volumes estimated for other patients we had treated so far.

Table 3: Types of Hernia, Side Affected and Estimated Hernia Volume

Type of Hernia	**Frequency**	**Percentage (%)**	**Mean (±SD)**
Indirect	16	80	
Sliding	4	20	
Total			
Side Affected			
Left	7	35	
Right	13	65	
Total	20	100	
Estimated Hernia Volume (mL)			
<2000	0	0	3039.75 (±319.90)
2001 – 3000	9	45	
3001 – 4000	11	55	
>4000	0	0	
Total	20	100	

Further measures and preparations were taken to ensure the anticipated challenges often encountered in the repairs of

GIH were overcome. The challenges mainly are loss of domain; respiratory difficulties; bowel ischaemia or injury; haemorrhage and wound complications. The patient was counselled. Giant inguinal Herniorrhaphy (the operation) was performed through a lower abdominal incision carried to the inguinal region for good access. Reduction was achieved through meticulous bowel dissection to prevent injuries to the bowel. The cord was preserved in all the cases to prevent cord compromise. The scrotal skin often shrinks back to normal anatomical size and, hence could not be used as a flap to enlarge the abdominal cavity as reported by some other workers (**Musa** *et al.,* 2023). Recovery was uneventful. We observed them and followed up for 6-months before final discharge from the clinic.



Before the operation **After the operation**

Fig. 23: Pictures of the presentations before and after surgery

Source: Musa-Olomu *et al*. (2023)



Fig. 24: The patient smiling after the operation

Mr. Vice-Chancellor, it is another evidence to show the beauty of surgeon's knife i.e., our knife is for beautification and the patients smiled after our surgery.

Cardiothoracic and Children Surgery Experience

Mr. Vice-Chancellor, because of the day-to-day activities of human beings, some groups are vulnerable to trauma, injury and infection (Ibrahim *et al.*, 2005), especially in the paediatric age group and in the adult (Abdul-Rahman, 2014). Nonetheless, the paediatric age group are more vulnerable and tends to react badly to trauma, injuries and infection with terrible complications because their immunities are not fully developed. **Musa** *et al*. (2003) treated two cases of pyomyositis and typhoid septicaemia that were complicated with purulent pericarditis. (pus in the sac enveloping the heart). The first case was 12 and the second was 14 years; they were both males. The patients were treated by draining under ultrasound guided through the Angle of Larey. And chest x-ray came back to normal after drainage immediately.



Fig. 25: Draining the Purulent Pericarditis pus

Source: Musa *et al.* (2003)

This is the demonstration of the technique and positioning of the patient and the doctor during the draining of the pus in the heart through the angle of Larey

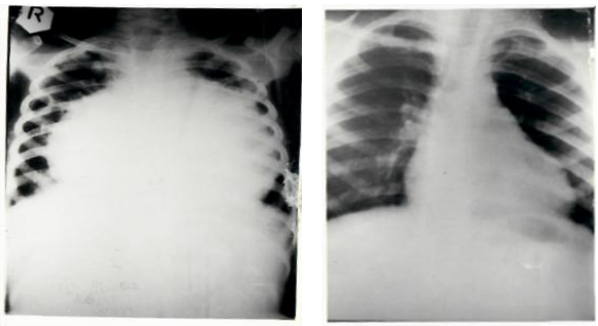

(a) Before Surgery (b) After Surgery

Fig. 26 (a&b): Chest X-ray shows before and after the drainage

Sources: Musa *et al.* (2003)



Fig. 27: X-ray of right fermor with pyomyositis and features of acute osteomyelitis

Sources: Musa *et al.* (2003)

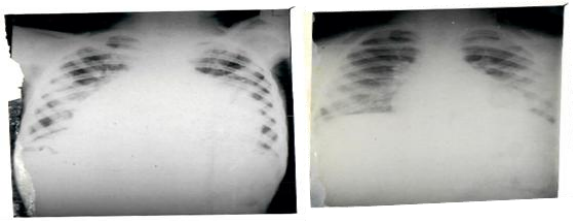

(a) X-ray before drainage (b) after drainage

Fig. 28(a&b): Chest X-ray before surgery, enlarge cardiac silhouette

Sources: Musa *et al.* (2003)

Mr. Vice-Chancellor, I am excited to tell this audience that we were the first, according to our records, to report ***''Purulent Pericarditis complicating typhoid septicaemia and pyomyositis''*** in an Africa population. In addition, the two patients are alive today listening to this lecture in this hall.

Upper Gastro-intestinal Bleeding (**Obstetrics and Gynaecology Experience**)

Gastrointestinal (GIT) bleeding is a dreadful symptom associated with a wide range of clinical disorders, some of which are primarily not related to the GIT. My General Surgery Team treated a 28-year-old woman who presented with an upper GIT bleeding complicating metastatic Gestational Trophoblastic Disease (GTD) (*Iju*), which was not diagnosed until my General Surgery team was invited.

Case Report: A 28-year-old Paral1^{+1} (has one child alive and currently carrying a pregnancy) woman presented at the Gynaecological Emergency Unit of our Tertiary Health facility in Nigeria with a-3-month history of amenorrhea and generalised body weakness of one-week duration. She had uterine evacuation four years earlier for a suspected hydatiform mole (*Iju*). Initial investigations revealed a haematocrit of 9% and positive urinary pregnancy test. She had an emergency pelvic exploration on a strong suspicion of ruptured ectopic pregnancy by the Obstetrics and Gynaecology (O&G) Team. Operative findings, however, showed a grossly normal and intact reproductive tract. Her rapidly declining haematocrit, inspite of blood transfusions and passage of black stool in the following week post-operative, necessitated referral to my General Surgery Unit (GSU) with a provisional diagnosis of upper GIT bleeding, possibly from chronic duodenal ulcer. However, this diagnosis was excluded by an emergency esophago-gastro-duodenoscopy (OGD) at the Surgical Unit.

Her deteriorating clinical condition necessitated an emergency surgical re-exploration (Laparotomy) that showed haemorrhagic jejunal tumours and an ileo-ileal intussusception. Histological examination of the excised specimen showed

features in keeping with metastatic choriocarcinoma. This report highlights the diagnostic challenges encountered in the management of a case of metastatic choriocarcinoma that presented with features of Upper GIT bleeding. Her clinical condition improved on chemotherapy and remained satisfactory on follow-up.

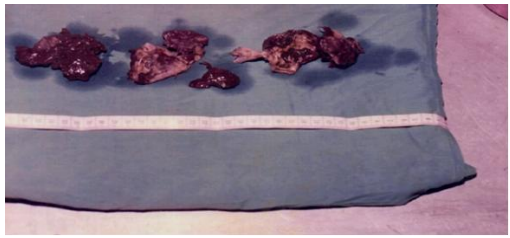

Fig. 29: Hemorrhagic tissue

Source: Musa *et al*. (2006)

Local Herbalist and Traditional Bone Setters

Currently, the medical services in our hospitals at all levels are sub-optimal, coupled with poverty, in-accessibility to orthodox medical services, cultural beliefs and attitude. Consequently, the patronage of herbalists and traditional bone setters is inevitable in our environment (Thanni 2000). Hence, there is preponderance of patronage of traditional bone setters **Musa** *et al.* (2004), reported an 18-year-old carpenter apprentice among others (70 cases in all), who was hit by a car on the right thigh. X-ray of the right thigh revealed a distal fracture of the1/3 of the right femur. The relatives absconded with the patient after initial resuscitation from shock to a traditional bone-setter. He applied a very tight cloth tourniquet just below the right knee (see the necrotic skin at the tourniquet site) (Fig. 31).



Figure 30: Mal-united Distal ($^{1}/_{3}$) third fracture of the right femur
Source: Musa *et al.* (2004)



Fig. 31: Tourniquet site with gangrenous amputation of the right foot
Source: Musa *et al.* (2004)

This probably made the severance of the popliteal vessel by posterior angulation of the distal fracture segment possible with consequent gangrene of the right leg. The patient lost the right foot in the process. He later represented to the hospital and subsequently underwent an above-knee amputation. He was thereafter rehabilitated with a prosthesis and had since returned to work. I came to the conclusion (the outcome of the treatment of the patient treated by herbalist) that ignorance, cultural beliefs and attitudes, poverty and inaccessibility to orthodox medical practice were some of the factors responsible for the patronage

of traditional healers (**Musa** *et al.*, 2004). Hence our knife is for beautification and patients smile afterwards.

Urological Experience- Treatment of Varicocele

The Vice-Chancellor Sir, experience in urological practice as a General Surgeon will be illustrated with few cases of infertility in men due to varicocele. Varicocele is defined as a dilatation of the veins draining the testis. According to the American Urological Association, varicocele is when veins become enlarged inside the scrotum (the pouch of skin that holds our testicles). These veins are called the pampiniform plexus. It is estimated that10 out of every 100 males have a varicocele. As earlier stated, varicocele is a common cause of infertility in men among others. Infertility in marriage is culturally blamed on women. However, studies have shown that approximately 35% of infertility cases are due to male factors, with varicocele being one of the most common causes (Ibrahim et al., 2015). In my practice as a General Surgeon, I have successfully treated over fifty (50) out of 55 men presenting with infertility characterised by low sperm count, poor sperm motility, and abnormal sperm morphology. Out of these fifty-five (55) patients, three cases are presented to illustrate our experience.

Summary of the Cases

The case presentations are more or less the same. Three couples presented with inability to get pregnant about 4, 6&8 years after marriage. All other parts of the history were essentially normal. However, as it is usually the norms to first examine the male and it was discovered that the husbands had bilateral scrotal varicocele. The results of their seminal fluid analysis before surgery revealed as follows (table 4). However, six months after the surgical operation of varicocelectomy, to correct the abnormality, there were improvements in the parameters as shown in (Table 5). All the families got children after our operation and were very happy (I presented as a paper at the International College of Surgeons Conference in 2004, Calabar Nigeria).

Table 4: Sperm Analysis of Patient before Surgery

	A	B	C
Volume	2mls (normal 2-6mls)	1.5mls	2mls
Motility	sluggish (straight and fast)	Sluggish	sluggish
Abnormal Forms	70% (10-30%)	75%	70%
Sperm count	2000/ml (20-80m/ml)	1000m/l	2000m/l

Table 5: Showing the Sperm analysis of the patient six months after surgery

	A	B	C
Volume	7.5mls	7mls	7.5mls
Motility	Fast & straight movement	Fast & straight movement	Fast & straight movement
Morphology	Normal shaped	Normal shaped	Normal shaped
Sperm count	200,000/ml	250,000/ml	250,000/ml

Varicocele simply refers to excess venous blood supply to the testes, thereby causing increase in temperature of the testes affecting the production of sperm and the viability of the sperm produced itself. It also brings up stagnation of the venous blood, reflux, inadequate oxygen supply to the testes for maximum function and other waste injurious products of metabolism into the process of sperm production from the renal vein and adrenal glands. The major aim and background of the operation (varicocelectomy) was to reduce the excess venous blood supply to the testes so that they could function normally to produce viable and normal sperms that could move properly with all its anatomic structures to be able to fertilise the eggs of the females. It is done manually or microscopically through the inguinal or sub-inguinal approach.

Happy Families and their Children after the Surgeon's Intervention



Fig. 32: Family (A) with three (3) children after nine (9) years of marriage (After varicocelectomy)

Source: Musa *et al.* (ICS 2004 Conference Paper)



Fig. 33: Family (B): Three (3) children after twelve (12) years of marriage (After varicocelectomy)

Source: Musa *et al.* ICS 2004 Conference Paper



Fig. 34: Family (C) with four (4) children after fourteen (14) years of marriage (After surgical intervention)

Source: Musa *et al.* ICS 2004 conference paper

All the families eventually had children and were very happy. The results of our surgery are perfectly in conformity with the topic of this lecture! ‘‘Surgeon’s knife will make you smile.’’

Community Service

Between 1999 and 2001, I was elected the Public Relations Officer (PRO) of the Medical and Dental Consultants Association of Nigeria (MDCAN), Olabisi Onabanjo University Teaching Hospital (OOUTH) Branch. Owing to my outstanding performance in that capacity, I was subsequently appointed Head of the Department of Surgery between 2003 and 2007, shortly after joining the services of Olabisi Onabanjo University (OOU) and OOUTH on July 1, 1999. During this period, I also served as a member of the University Senate (2003–2007) where I contributed meaningfully to institutional policy and academic development. From 2000 to 2008, I served as the Consultant and the Coordinating Lecturer at OOU and OOUTH respectively, playing an active role in the training of undergraduate medical students and postgraduate Resident doctors, thereby strengthening the integration of academic institution with clinical practice. Notably, after leaving OOU and OOUTH in 2010, I returned back to OOU as a Ph.D. student in Anatomy (while serving as an Associate Professor of Surgery at the University of Ilorin). I was graciously invited by Prof. Adenowo, the then Head of the Department of Anatomy, to lecture B.Sc. Anatomy students and supervise their research projects-a role I diligently performed from 2010 to 2022, contributing immensely to the academic growth of the department and the mentorship of future scholars.

Trainees

I have successfully trained several Consultant General Surgeons, some of whom have risen to professorial rank in their respective institutions. Notable among them are Dr O. Adekoya (OOU, Ago-Iwoye/OOUTH, Sagamu) and Dr. O.A. Musa (UITH). In addition, I have supervised and mentored several Ph.D. candidates in Anatomy, providing academic guidance and

professional counselling throughout their training. I served as the General Surgeon Consultant to Muslim Hospital in Saki, Oyo State. Following my appointment at the University of Ilorin Teaching Hospital on June 1st 2010, I was appointed the Consultant in charge of one of their rural outreaches at the Muslim Ummah Hospital in Kishi. My work in both centres received commendation from the then Governor of Oyo State, His Excellency, Governor Adebayo Alao-Akala (of blessed memory), who delegated his Commissioner for Health to visit Kishi in recognition of the services I rendered. The Commissioner recorded the following remarks in our Visitors' book:

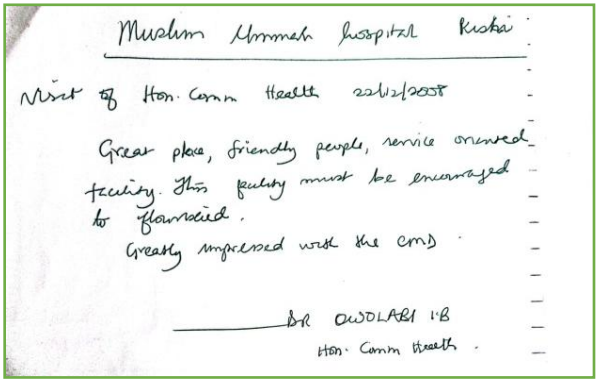
Muslim Ummah hospital Kishi

Visit of Hon. Comm Health 22/12/2008

Great place, friendly people, service oriented facility. This facility must be encouraged to flourished.

Greatly impressed with the CMD

DR OWOLABI I.B

Hon. Comm Health

''<u>Muslim Ummah Hospital Kishi</u>
Visit of Honourable Commissioner of Health 22/12/2008
Great place, friendly people, service-oriented facility.
This facility must be encouraged to flourish.
Greatly impressed with the CMD (me).

– Dr. Owolabi I. B
(Hon. Commissioner of Health)''

At the University of Ilorin and UITH, I served as:

a. Head, General Surgery Unit III, 2011-2017, a unit created to cater specifically for laparoscopic surgery, thyroid surgery and specialised hernia care

b. Chairman, Committee on Hospital Services Pricing at UITH (2015-2017)

c. Member, Postgraduate Research Committee, Department of Surgery (2011-2017)

d. Member, University of Ilorin Senate (2025-Date)

e. Course Adviser, 400-600 Medical Students rotating through surgery (2011-2017; 2015-Date)

At the **National Level**

a. Worked with the *Guardian Newspaper* to create the awareness of goitre, causes, prevention and treatment of goitre (1999-2010)

b. Worked with the *NATION Newspaper* on the causes, prevention and treatment of goitre as well as to disabuse the minds of the populace against the myths and misconceptions about its causes (1999-2014)

c. Worked with Kishi and Saki communities in Oyo State (1998-2011)

My Sojourn at the Federal Medical Centre, Abeokuta

Mr. Vice-Chancellor, I resumed at Federal Medical Centre, Abeokuta, as the Chief Medical Director/Chief Executive Officer on 10/7/2017. Upon resumption, I immediately set the ball rolling after my initial two (2) weeks of inspection of all the offices to identify the amount of tasks before me. I feel extremely happy to reveal to this auspicious audience that within 3 years, we had provided all the necessary equipment, and infrastructure that were needed; hence, when SERVICOM from the Presidency came to assess us, we were rated as the best FMC in 2020, ditto 2022 (we still maintained our lead) as well as in 2024, when the Federal Ministry of Health, Abuja (FMOH) awarded us with the ***Best Customer Friendly and Environmentally Clean Hospital*** in the country with a cash gift of N500,000. Today, FMC Abeokuta is actively engaged in open-heart surgery, and I am proud to state that the Centre currently performs approximately 40% of all the open-heart

surgeries in Nigeria, according to the Cardiothoracic Association of Nigeria. To crown it all, I was conferred with the ***Award of the Best and Most Outstanding Medical Director*** in the country on 22nd June, 2024 by African Stride International Media Group (ASIMGROUP).

Nonetheless, the most significant achievement remains the establishment of the ***Federal University of Medicine and Medical Science, Abeokuta*** **(FUMMSA)**. This is an opportunity that eluded the Egbas, 77 years ago (since 1948), when the current University of Ibadan was initially brought to Abeokuta, but was rejected. Today, I brought the glory back to Egbaland, because I initiated the process in 2017 as the CEO/MD of FMC, Abeokuta. I worked tirelessly at every stage of its establishment to see to its take-off. I am happy today that I am the brain behind FUMMSA.

Associations and Unions

I served as prefect in charge of Islamic Affairs as well as the Student Imam in my secondary school between 1976 and 1977. Subsequently, I had a very rare opportunity of being chosen as the Imam of Muslim students in all the Institutions I attended Ogun State Polytechnic (1979-1981), now MAPOLY; Student Imam of Kuti Hall at University of Ibadan, as well as Alexander Brown Hall in UCH (1983-1986). Also, during my House-Officership training at OOUTH, I was made the Imam in 1986 and I had the opportunity of establishing the praying of Jumat Solaat in the Teaching Hospital till today. I am a member of NMA Ogun, Kwara; International Brain Organization, Anatomical Society of Nigeria as well as the Sister Association (Clinical Anatomists of Nigeria), Medical & Dental Consultant Association of Nigeria (MDCAN), UITH, ASUU, University of Ilorin.

I have been a staunch member of MSS from 1973 till date and was appointed the Chairman of the Oyo-State chapter (1985-1986). I am also a member of Islamic Medical Association of Nigeria as well as a Fellow of International College of Surgeons (FICS).

Conclusion

Mr. Vice-Chancellor, it is obvious from my lecture that General Surgeons are the real Surgeons and are the most invaluable in academics as well as in hospital services generally. This is because, General Surgery Curriculum/Syllabus constitute more than 70% of both undergraduate and postgraduate medical trainings. In medical services, aside from their primary speciality as General Surgeons, they can comfortably manage patients of other subspecialties as elucidated in this lecture. This is corroborated by the majority of our patients that were professionally treated and smiled at the end of our surgery as well as a good number of patients in other subspecialties; hence, the *Beauty of a Surgeons' Knife that Brings Smiles to the Patients' Faces"*.

Recommendations

Mr. Vice-Chancellor, it is my pleasure to recommend that all the challenges and problems that have been identified in this lecture are addressed through the following actions, namely:

A. The General Public

1. The general populace should re-examine myths and cultural beliefs and seek expert medical care promptly.
2. People should ensure adequate and early patronage of hospitals
3. Parents and guidance should ensure protection of children and counselling to avoid unnecessary injuries. Whenever the children are injured, early and immediate reporting in the hospital is necessary; as they are the most vulnerable to injury, and to avoid complication.
4. Public should avoid food items that are likely to encourage development of goitre such as garbage, excessive use of drug that are not prescribed by doctors.
5. People should try as much as possible to avoid or stay near (Garri processing mills) to prevent the inhalation of cyanide fumes that can cause goitre.

6. Public should keep strictly to prescription of their doctors as excess of drug usage can cause problems like development of goitre in diabetic, hypertensive and patient on cough medication.

7. People should avoid patronage of quack doctors as well as traditional bone setters.

B. Government at all levels-Federal, State and Local Governments

1. Government at all levels should ensure that our local and traditional Garri producers are trained on how to properly process and produce garri to ensure cyanoclycosides are removed to safety levels

2. The Federal Government should focus on the training of more General Surgeons because based on the nature of their training, they can function anywhere, treating their patients in their primary area of specialisation and effectively managing the patients of other specialities of surgery effectively. Hence, they can be posted to anywhere in any part of the country both rural and urban and function excellently well.

3. The Nigerian Medical Association NMA should collaborate with General Surgery yearly by declaring General Surgeons' Day (GSD), as I am aware of the Physicians' Week, every year.

4. Government at all levels should ensure access to well treated portable water in all the nooks and crannies of the country to reduce incidence of goitre; and to promote the use of iodised salts.

5. Local Government Institutions should encourage community extension health workers to ensure more health counselling that can encourage our people to patronise orthodox medicine and disabuse their minds away from cultural beliefs and attitudes and the wrong notion they have about orthodox medical practice.

6. State and Local Governments, in particular, should regularly organise training for traditional bone setters, as it is done for Traditional Birth Attendants to offer safe care to the populace.

7. To mitigate the widespread poverty currently ravaging the land currently, the Federal Government should ensure the provision of Health Insurance Scheme, with a view to making it more accessible to a vast majority of people to make healthcare affordable.

C. University of Ilorin and UITH

8. The UITH Management as well as the management of other Tertiary Health Institutions in the country should mandate their staff members to give prompt attention to patients, when they come to hospitals.

9. Federal Government should create the Office of the Surgeon General of the Federation as handed over by the colonial masters and to make sure doctors and other healthcare workers' salaries are the next after that of the Speaker of the Honourable House of Representatives.

ACKNOWLEDGEMENTS

Vice-Chancellor Sir, my very deep appreciation goes, first and foremost, to Almighty Allah (SWT), my creator, The All-knowing, The Wise and the Lord of the Worlds. All Glory, and Adoration belong to Him, and I sincerely thank Him and Praise Him as well, for granting me the special grace to navigate through my academic and clinical careers to this very auspicious level. I also give thanks to the University Authority, for the very rare honour bestowed on me in appointing me a Professor and the University of Ilorin Teaching Hospital, for providing the conducive and peaceful environment for me to thrive successfully. I am most grateful. However, I sincerely thank the Vice- Chancellor, Professor Wahab Olasupo Egbewole, and as well as other Principal Officials of the University, including all the Deputy Vice-Chancellors, for the vital roles they play in the success that I am celebrating today. I specifically thank the Chairman, Library and Publications Committee, Professor A.O. Issa, for all the efforts he made towards the success of this lecture.

I thank Allah the Almighty again, especially for the type of parents He gave me-Late Alhaji Chief Imam Akanbi, Musa-Olomu Alli and Late Alhaja Wulaimah Abeun Musa-Olomu (Nee Afonja). The type of love, affection, care, home-training, parental counselling given by these special parents to me and my siblings were second to none. I fervently pray to Allah to forgive their mistakes and put them in the highest place in Aljanah-fridaus-Aamin. I sincerely thank my step mother, Alhaja Shifawu Ajiun Musa-Olomu. I am also grateful to my other step mothers; Alhaja Wasilat (Nee Otitoloju) and Hajia Zinnat. May God bless them all. I am grateful, too, to my father's in-laws, especially the Afonja family of Yewaland, my maternal grand-father (Papa Suberu Kolawole Afonja) and maternal grandmother (Mama Asimowu Afonja) as well as Akinyemi Family. All my in-laws, especially the ubiquitous Bello family of Egbaland.

My other sisters and brothers-Auntie Hahrat Bamgbola, Rafatu Adeogun, Muyibatu Gbese oyemi, and late Brother Rasheed Alade – all of blessed memory, I appreciate all you did for the care you gave me while I was young. To the current head of our family, Alhaji Imran Ayinde, and to Sister Sherifat Kilasho, Prof. Abdul Nafi''i and Dr. Akintunde Misbau – I am sincerely grateful for your kindness and support always. May Allah reward you all abundantly and all your family members.

I sincerely appreciate Alhaji Salami-Olomu family, especially Mr. Abdus-Sataar, Salman Olomu and others. My very deep appreciation also goes to Junaid-Olomu family, the Adeyemi and to Adeyinka family in Ijaiye, Abeokuta (Isale Idi-iroko), as well as Agbedeyi family, Mariam Afonja, Alh. Ibrahim Afonja, Akanbi and Hassan Afonja, Idayat Afonja and all others.

I want to appreciate all my primary school teachers at Nawair-Ud-Deen Primary School, Oke-Ijeun, Abeokuta, who did a lot to lay a very solid foundation for our educational career in life. I, therefore, sincerely appreciate our Headmasters, Mr. Dada, Alhaji Ayodeji, Mrs. Akinmade, Mrs. Alhaja Badmus, Mr. Ogunsanwo, Mr. Akins, Mama Mrs. Odubela, Mr. Adesina just to mention but a few including the two Mallams (the younger and the elder), I sincerely appreciate you all.

My secondary school teachers were really wonderful, right from our Principal, Alhaji S. O. Oyadina, Mr. Aina, Mr. Shodipe, Mr. Sopeyin, Mr. "Search Me", Major Badmus, Mallam Raaji, Mr. Tajudeen Shokunbi, Mr. Mukaila Ogunleye, Mr. Akinsola Mukaila, Mr. Shittu, Mr. Faturoti, Mr. Mojo ''70, Mr. Fisulu; all my class-mates, Alhaji Orunsolu, Hafeez, Mohadiyyu Kadiri, Olalekan Saheed, Sesan Fadipe, Taofeeq Kasali, Dr. Sotiloye Sunday, Ogunwolu Ridwan, Mr. Salmaan Sobanke, Sikiru Faloye and all other NUDGOSAs world-wide. I appreciate you all.

All my lecturers at the Ogun State Polytechnic, now Moshood Abiola Polytechnic (MAPOLY), Prof. Dr. Bamiro, Dr. Okunmoren, Mr. Adesina, Mr. Hassan, Mrs. Apampa, Mr. Kuti,

Dr. Craig and a host of others. I thank you all for all you did to bake me very well for future. I sincerely thank you all. I also thank all my classmates at the Higher School Certificate level (HSC) Class in 1979-1981; you are wonderful people. I still have in my memory how you nick-named me - BIG BROTHER, the day I came out to solve a very knotty Physics question in Physics (on Light), which our Physics Master then had thought none of us would be able to solve. I enjoyed your company and thank you all.

At the University of Ibadan Medical School, its only Professor Amure, the Physiology lecturer and Pssada Rao (the Indian Biochemistry lecturers) at the pre-clinicals that I could recollect their names. However, I sincerely thank you all including all the other lecturers at the clinicals and all my classmates of 1981-1986 UI-Medics, but I cannot fail to mention Professor B.L. Salako (former Provost of our College, former DG NIMR & his wife, Mrs. Biola Salako), Professor Jimoh Ghaffar, Ojebuobur', Professor Olaopa, Prof. Fatai Olatunji, Dr. R.O. Suara, Dr. Olagunju and others. I thank you all for being good classmates. I can never forget my indefatigable teachers at the postgraduate levels, especially during my residency training at University College Hospital, Ibadan between 1991 and 1998. All my mates during the training, and especially, the erudite Senior Registrars like Prof. Yaweh, Prof. Malomo, Prof. Irabor, Dr. Adah, Dr. Sangoseni and a host of others. I cannot forget, that, that training afforded me the greatest opportunity in life to train under world recognised seasoned surgeons like Prof. O.O. Ajayi, Prof. O.G. Ajao, Prof. A. Adekunle, Prof. J.K. Ladipo, Prof. O. Akute, Prof. C.O. Adebamowo, Prof. O.B. Shittu, Prof. Okeke, Prof. Adegboye, Prof. Ogundiran, Prof. Afolabi, Prof. Ogunlade, and Prof. Lawani. I sincerely appreciate you all. During my Master programme in Anatomy at University of Ilorin, it was quite interesting. I thank Dr. Enaibe, Prof. Akinola, and others.

Nonetheless, the Ph.D. programme me at Olabisi Onabanjo University, Ago-Iwoye, Ogun State was more interesting with

Prof. Adenowo and my classmates, I sincerely thank you all. Prof. Adenowo specifically taught me dermatoglyphics, the art of diagnosing cancer by digital finger prints with background knowledge of genetics. You are well appreciated.

I am extremely grateful to my mentors, Prof. O.S. Noibi, Emeritus Prof. I.O. Oloyede, former JAMB Registrar, Prof. Yusuff Ola-Olu Alli (SAN), Prof. Aderinoye, Prof. Rasheed Raaji, Alhaji Kunle Saani, Dr. Amao Alaga, Baba Onisu and his wife and other friends, and colleagues, especially, from Muslim Students Society of Nigeria (MSSN). I thank Alhaji Kamaldeen, Dr. Kushimo, and Mr. Waheed Quadri, Chief RAM, Dr. Adetunji of Veterinary Department University of Ibadan.

I thank all my colleagues at Olabisi Onabanjo University/Teaching Hospital, Ago-iwoye and Sagamu respectively. I can never forget to mention Profs. Shonubi, Ayoade, Tade, Lateef Thanni, Dr. Salami, and Dr. Akiode, Profs. Adigun Lawal, Nasir Ahmed, all consultants in surgery UITH and all my residents in surgery then. I thank and sincerely appreciate you all. I enjoyed my stay at UITH Ilorin, Professors Adeoye, Kuranga, Adigun Lawal, Omokanye, Olaloke, Agodirin, and HoD, Abdur-Rahman, Ademola. I sincerely appreciate you all. Dr. Fasiku and Dr. Aremu and all residents in Surgery; and thank you dearly Mr. S.A Amosa, Mr. G.O. Yusuff, Mr. Muhammad, and all the people I worked with at Kishi annex of UITH, at Muslim Ummah Hospital, Ummah UITH, I sincerely thank all of you. Both Colleagues, Elders in FCS, COHS Unilorin among whom are Prof. T. Akande, Bolarinwa, Ameen, Uthman, Prof. WBR Johnson and all other academic colleagues.

All the people of Shaki and staff of Muslim Hospital Saki as well as Baptist Hospital, Saki. I thank you all. All the staff members, Management Committee members of Federal Medical Centre, Abeokuta, and specifically my Public Relations Officer, Mr. Orisajo, Mr. Samuel, Mr. Olowoyo Emmanuel, Abu Azeez, Mrs. Aramide, Mr. Olutunde, Pastor Wonah, Mr. Matanmi

Olumuyiwa, Mr. Atanda, Alfa Shamsudeen, Alhaja Bakare, Mrs. Orunsolu -sikiru and others. I thank you all. All the members of FMC Abeokuta Muslim Community, I appreciate you all. Please continue the good works you are doing, to make FMC, Abeokuta great among the Tertiary Health Institutions in the country.

I move to our Royal fathers and the first on the list is: The Paramount ruler of Egbaland, HRM Alake of Egbaland, followed by Obalaju of Jogga-Orile (where my mother hailed from) in Yewa North of Ogun State, Baale of Olomu village (where my father hailed from), Okere of Saki, Iba of Kishi and a host of other royal fathers here today, I sincerely appreciate you all.

I will also like to appreciate retired CP (Commissioner of Police) Dr. Olayinka Balogun, his PA (Personal Assistant) Mrs. Mulikat Oyeleke, Imam Ishaq Abolore, Imam Moshood Ahl-Sunnah Saki, Alhaji and Alhaja Ismail Olanrewaju, Mr. Faisah and Engineer Adul-Azeez Surveyor, and all Ahl-Sunnah Muslim Jamma in Saki. Also, Barrister Bayo Shittu (former Minister of Digital Economy). Former Rector MAPOLY, Alh. Waheed Kadiri, Mallam Y.K.A. Kareem and Y.K.O. AbudlKareem and Mr. Daniel Akinyemi for the typing and administrative works. Professor Issah, Nasir Adeoye and Abdul Rahman and Adedimeji, for reading the text.

Mr. Vice-Chancellor, Allah Almighty be praised for blessing me with a wonderful and resourceful family, He (God) stood solidly behind me. To all my children, I am very proud of you all, starting from Dr. (Mrs.) Ayodele (Nee Musa-Olomu) Ummul-Khayr; the husband, Barrister AbdulFatai Ayodele and my grandchildren, AbdulFatai Junior, ‘libat and Ahmead, Dr. Muhammad, Dr. Muzzammil Ameer, Dr. Umm-Salamah, Dr. Mutolib, Ummulaiman, UmmulKulthuum, Muminat, Abdullah and Habeebah, Please continue to maintain a very peaceful co-existence amongst yourselves. It is my fervent prayer that as Prophet Muhammad had encouraged Muslims to multiply so that his followers could outnumber the followers of other Prophets of

Allah on the day of Judgement; I fervently pray Allah Almighty to count us all among His devout servants – Amen.

I sincerely thank Allah the Almighty, for endowing me with beautiful, diligent and hardworking wives. Dr. (Mrs.) Aminat, a Consultant Community Physician, is one of them. She is really a very good woman and showed every understanding. I thank you profusely. Alhaja Salmah Musa-Olomu the second is also a very good partner with ideal character. I can never thank you enough. I found you useful in all the necessary areas. However, the first wife, the Associate Professor Dr. (Mrs.) Monsurat Titilayo Musa-Olomu, is the most outstanding. She did everything to contain my excesses. She kept giving me all the necessary support, advice, cooperation, understanding and assistance. I have never seen a beautiful partner like her. She kept helping me in my research works; hence we co-authored several research papers and publications that had to do with psychology and surgical patients. We operated many patients together in the theatre. She assisted me severally in many surgical operations. Titilayo, Folashade Ashani, you made my life, and I can never forget you. I am extremely proud of you.

To the audience, physical and virtual, I thank you all for listening.

REFERENCES

Achinewhu, S. C., & Owuamanam, C. I. (2001). Garification of five improved cassava cultivars, physicochemical and sensory properties of gari yield. *African Journal of Root and Tuber Crops, 4*(2), 18–21.

Adeniyi, T. D., Bejide, R. A., & **Musa, A. A.** (2013). Cyanide cytotoxicity and the follicular cells of thyroid gland in male wistar rats. *Research Journal of Health Sciences, 1*(1), 45-55.

Adenowo, T. K., & Dare, B. J. (2016). Digital and palmer dermatoglyphic: A bio-indicator for intelligence quotient. *Journal of Basic and Applied Research, 2*(3), 313–319.

Adenowo, T. K., & Oladokun, O. P. (2019). Topographic palmar crease analysis at different levels of academic performances in college students. *International Journal of Recent Innovations in Academic Research, 3*(5), 197–202.

Adeoye, P. O., Kadri, D. M., Bello, J. O., Ofoegbu, C. K. P., Abdur-Rahman, L. O., Adekanye, A. O., & Solagberu, B. A. (2014). Host, vehicular and environmental factors responsible for road traffic crashes in a Nigerian city: Identifiable issues for road traffic injury control. *Pan African Medical Journal, 19*(159) https://doi.org/10.11604/ pamj. 2014.19.159.5017.

Alter, M. (1967). Dermatoglyphic analysis as a diagnostic tool. *Medicine, 46*(1), 35–56. https://doi.org/10.1097/00005792-196701000-00002

Aunac, S., Carlier, M., Singelyn, F., & De Kock, M. (2002). The analgesic efficacy of bilateral combined superficial and deep cervical plexus block administered before thyroid surgery under general anesthesia. *Anesthesia & Analgesia, 95*(3), 746–750.

Brunicardi, F. C., Andersen, D. K., Billiar, T. R., Dunn, D. L., Hunter, J. G., Kao, L. S., Matthews, J. B., & Pollock, R.

E. (2019). *Schwartz's principles of surgery* (11th ed.). McGraw-Hill.

Egan, R. J., Svensson, J. P., & Smith, M. (2013). Randomized clinical trial of intraoperative superficial cervical plexus block versus incisional local anaesthesia in thyroid and parathyroid surgery. *British Journal of Surgery, 100*(13), 1732–1737. https://doi.org/10. 1002/bjs.9292

Ellis, H., & Mahadevan, V. (2010). *Clinical anatomy: Applied anatomy for students and junior doctors* (12th ed.). Wiley-Blackwell.

Hegedüs, L., Karstrup, S., & Rasmussen, N. (1986). Evidence of cyclic alterations of thyroid size during the menstrual cycle in healthy women. *American Journal of Obstetrics and Gynecology, 155*(1), 142–145.

Herbland, A., Cantini, O., Reynier, P., Valat, P., Jougon, J., Arimone, Y., & Janvier, G. (2006). The bilateral superficial cervical plexus block with 0.75% ropivacaine administered before or after surgery does not prevent postoperative pain after total thyroidectomy. *Regional Anesthesia and Pain Medicine, 31*(1), 34–39.

Ibraheem, G. H., Nasir, A.-R. A., Babalola, O. M., Abdur-Rahman, L. O., & Solagberu, B. A. (2025). Patterns of trauma presentation in Ilorin, Nigeria: A 15-year review. *Ethiopian Journal of Health Sciences, 35*(1), 35–39.

Ibrahim, A. G., Aliyu, S., Ali, N. and Lawan, A. M. (2015). Varicocele associated infertility in Maiduguri North Eastern Nigeria", *International Journal of Current Research, 7*(5), 17432-17434.

Information Nigeria. (2017). *Woman all smiles after massive goitre was removed from her neck (Photos).* https://www.informationng.com/2017/08/woman-smiles-massive-goitre-removed-neck-photos.html

Koch, B. M., Sibbesen, O., Swain, E., Kahn, R. A., Du, L., Bak, S., Halkier, B. A., & Møller, B. L. (1994). Possible use of a biotechnological approach to optimize and regulate

the content and distribution of cyanogenic glucosides in cassava. *Acta Horticulturae, 375(2),* 45–60.

Krassas, G. E. (2000). Thyroid disease and female reproduction. *Fertility and Sterility, 74*(6), 1063–1070.

Musa, A. A., & Adebayo, S. B. (2007). Misdiagnosing epigastric hernia. *Archives of Nigerian Medicine and Medical Sciences, 4*(1), 34–40.

Musa, A. A., Adebayo, S. B., Banjo, A. A. F., & Oyewole, E. A. (2008). Emergency partial thyroidectomy under cervical block to relieve severe acute airway obstruction from thyroid cancer. *African Health Sciences, 8*(3), 186–189.

Musa, A. A., Agboola, O. J., Banjo, A. A., & Oyegunle, O. O. (2010). The use of drains in thyroid surgery. *Nigerian Postgraduate Medical Journal, 17*(1), 15–18. https://doi.org/10.4103/ 1117-1936.181416

Musa, A. A., Banjo, A. F., Oladapo, O. T., Agboola, A. O., Akindipe, J. A., & Okewole, I. A. (2006). Metastatic choriocarcinoma of the small bowel presenting with features of upper gastrointestinal bleeding. *Case Reports and Clinical Practice Review, 7(1),* 224–227.

Musa, A. A., Banjo, A., Agboola, O., & Osinupebi, O. (2012). Failure to heal of thyroidectomy wound due to gossypiboma and stitch sinus: Report of two cases. *Journal of Surgical Technique and Case Report, 4*(1), 24–26. https://doi.org/10.4103/2006-8808.100349

Musa, A. A., Lasisi, O. A., Fatungase, O. M., & Oyegunle, O. A. (2009). General and regional anaesthesia for thyroidectomy in rural/semi-urban Nigerian centres. *East African Medical Journal, 86*(6), 287–290. https://doi.org/10.4314/eamj.v86i6.54141

Musa, A. A., Musa, M. T., & Baba, I. (2014). Cultural beliefs and attitudes: The psychosocial and economic problems associated with goiter and thyroidectomy in an African population. *Thyroid Research and Practice, 11*(1), 22–25. https://doi.org/10.4103/0973-0354.12419 1

Musa, A. A., Ogun, S. A., Agboola, A. O. J., Shonubi, A. M. O., Banjo, A. A. F., & Akindipe, J. A. (2007). Surgical complications from local herbal practitioners: Report of five cases. *East African Medical Journal, 84*(5), 240–245. https://doi.org/10.4314/eamj.v84i5.9532

Musa, A. A., Salami, B. A., & Tade, A. O. (2003). Purulent pericarditis complicating septicaemia: Report of two cases. *East African Medical Journal, 80*(6), 331–333. https://doi.org/10. 4314/eamj.v80i6.8711

Musa, A. A., Shonubi, A. M. O., Oyewole, E. A., Tade, A. O., Salami, B. A., Akindipe, J. O., & Ajayi, O. O. (2005). Inadequate anaesthetists: Thyroidectomy under bilateral superficial cervical plexus block. *Archives of Nigerian Medicine and Medical Sciences, 2*(2), 11–15.

Musa, A. A., Yekeen, T. G., & Adebiyi, W. A. (2006). Thyroidectomy without endotracheal intubation in a rural setting: Our experience. *Nigerian Medical Practitioner, 50(2)*, 120–122.

Musa-Olomu, A. A., Musa, T. M., Adeleke, N. A., Abdulraheem, N. T., & Ajape, A. A. (2023). One stage repair of giant inguinal herniae: A feasible option. *The Egyptian Journal of Surgery, 42*(3), 1110–1121. https://doi.org/10.4103/ejs.ejs_143_23

Padmaja, G. (1995). Cyanide detoxification in cassava for food and feed use. *Critical Reviews in Food Science and Nutrition, 35*(4), 299–339. https://doi.org/10.1080/1040839950952 7703

Pearce, L. L., Bominaar, E. L., Hill, B. C., & Peterson, J. (2003). Reversal of cyanide inhibition of cytochrome c oxidase by the auxiliary substrate nitric oxide: An endogenous antidote to cyanide poisoning. *Journal of Biological Chemistry, 278*(52), 52135–52145. https://doi. org/10.1074/jbc.M306648200

Russell, R. C. G., Williams, N. S., & Bulstrode, C. J. K. (Eds.). (2005). *Bailey & Love's short practice of surgery* (24th ed.). Arnold.

Shonubi, A. M. O., **Musa, A. A**., Salami, B. A., Shotimehin, S. A., & Sule, G. A. (2004). Femoral hernias in children at the Olabisi Onabanjo University Teaching Hospital, Sagamu, Nigeria. *East African Medical Journal, 81*(9), 447–450.

Thanni, L. O. A. (2000). Factors influencing patronage of traditional bone setters. *West African Journal of Medicine, 19*(3), 217–220.

The Guardian. (2014). Pain in the neck: Relief for goitre, 47 treated, more to undergo surgery. *The Guardian*, p. 18.

The Nation. (2014). Goitre-infected community where victims reject medical help; blame plight on witches and wizards. *The Nation*, p. 14.